

# TRIPLE TIBIAL OSTEOTOMY (TTO)

## Introduction

Injury to the cranial cruciate ligament (CCL) is the most common cause of lameness in the hind limb of dogs. Please refer to the CCL pamphlet available on this site for further general information. Tibial tuberosity advancement (TTA) was developed in 2004 and is one of a number of surgical procedures available to address CCL injury.

Corrective osteotomies (Tibial Tuberosity Advancement (TTA), Tibial Plateau Osteotomy (TPLO), Triple tibial Osteotomy (TTO) and Tibial Wedge Osteotomy (TWO)) all involve cutting the shin (tibia) bone in a variety of way to adjust the way in which the knee joint works such that the need for a functioning CCL is overcome.

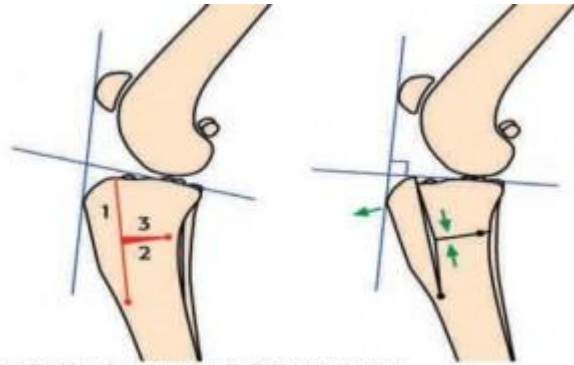
Each procedure has its relative pros and cons, and no single procedure is ideal for every patient. Careful patient assessment and selection is critical to optimise the surgical outcome.

Generally it is accepted that the majority of the above osteotomies result in the knee (stifle) joint developing less osteoarthritis (OA) over time when compared to conservative management or other current surgical techniques. Concurrent damage to other structures such as the menisci (cartilage pads within the joint) also has an important role in future development of OA within the joint.

## TTO Surgery

TTO surgery involves cutting the shin bone (tibia) in three places, removing a small wedge of bone and then applying a surgical steel plate. This alters how the knee joint works in such a way that a CCL is no longer required to provide stability within the joint.

Once the bone has healed the implants become redundant, and all of the stresses are carried through normal bone, tendons and muscle. Therefore once healed, the implants are not prone to future fatigue and breakage as can occur with some other repair techniques. The implants are left in place for the rest of the dog's life unless they cause a clinical problem (very rare).



From Veterinary Instrumentation, Sheffield, www.vetinst.com

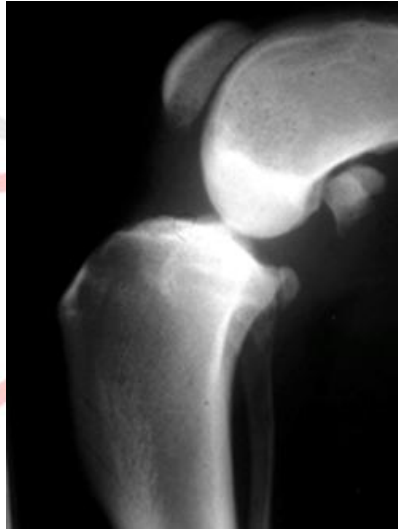


Figure 1. X-ray of a normal stifle joint.

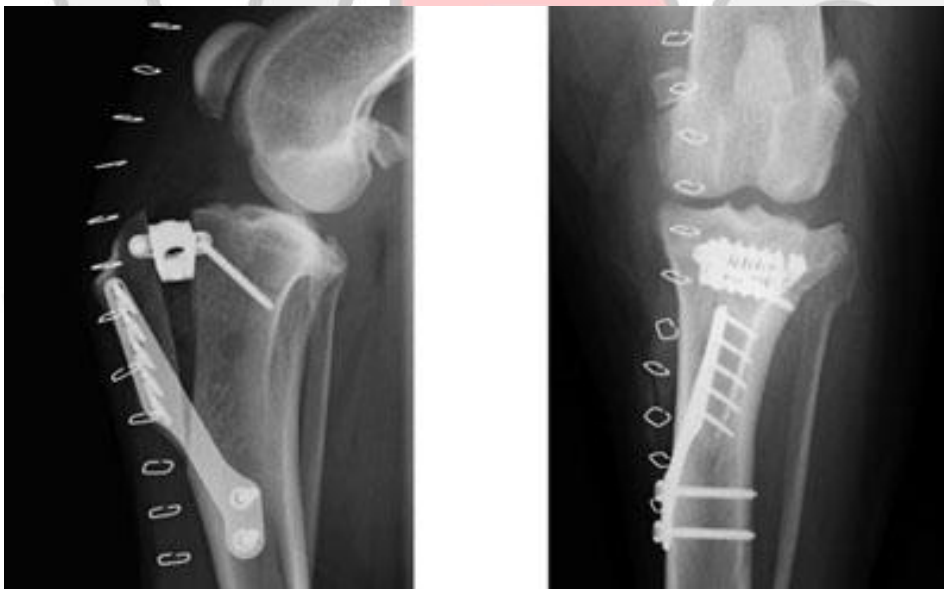

Figure 2. Stifle joint X-ray after having a TTA performed.

## Postoperative Care

Your dog will have had an epidural before surgery and will usually have been kept in the clinic for 24-48 hours to allow careful management of any post-operative pain.

They will usually be walking on the limb within 12-24 hours however a mild degree of lameness may be present for 2-4 weeks postoperatively.

When you collect your dog they will usually have the wound covered with an **adhesive dressing which may be removed within 3-5 days**, or earlier if the dressing gets dirty or has exudates leaking through it.

**Sutures should be removed 10-14 days after surgery.**

**Follow up X-rays will need to be performed 6 weeks after the surgery** to assess the amount of healing of the bone, as this will determine when the dog can return to normal exercise.

You should anticipate that your dog will need **6-8 weeks of STRICT REST in a controlled environment**. If your dog needs to walk over a slippery surface or down 1-2 steps for access outside then a towel may be placed around the stomach just in front of the hind limbs to help ensure that they can be supported if their feet slip from under them.

If at any point during recovery the lameness seems to significantly worsen then you should revisit your surgeon immediately and X-rays may need to be performed to assess the surgical site.

## Physiotherapy

Physiotherapy is very important to optimise the recovery of your dog after surgery.

**Passive range of movement (PROM) exercises** are designed to maintain joint and muscle mobility throughout the limb. They can be started from two days postoperatively and should be continued throughout the recovery period.

Gentle flexion and extension of the affected limb should be performed with the limb being held in the flexed or extended position for 5 – 10 seconds. This should be repeated for 5 to 10 cycles at a time and repeated regularly throughout the day.

The PROM exercises should work within the comfort limits of the animal, and should never force a joint beyond the comfort threshold. Over time the range of comfortable motion will improve.

**Dynamic range of movement (DROM) exercises** are used to redevelop muscle strength in the affected limb.

- **Controlled leash walking:** Starting from 2 weeks after surgery your dog may be taken for 5 minutes leash walking 3-4 times daily. This should be done in an environment with good non-slip footing (concrete / grass etc). Over the next 4 weeks this may gradually be increased to 10 minute walks 3-4 times daily. And then after the follow up X-rays this may be increased further with guidance from your surgeon.
- **Figure eights:** These may be started from 4 weeks after surgery. Initially the dog should be gently walked through large figure eights when out on leash exercise. Then over the next 4-8 weeks the figure eights can slowly be reduced in circumference and performed more rapidly. They should only ever be performed where there is good footing.
- **Incline and decline walking:** From 6 weeks after surgery you may slowly leash walk your dog across a slope while alternating which limb is on the uphill side. They may also walk up and down slope. Over time you may increase the speed of the walking and slope of the hill used.
- **Sit / stand exercises:** After the 6 week follow up X-rays you may start this exercise. When leash walking, stop and allow your dog to start sitting; just before their bottom touches the ground make the dog walk on, forcing them to push off with their hind limbs.
- **Hydrotherapy / underwater treadmill:** May be initiated from 4 weeks after surgery. Please discuss with us potential locations to undertake hydrotherapy and we will contact the therapist to discuss your animal's program. Care must be taken with free swimming as it can be overly stressful for the knee joint. Please discuss this with your surgeon before starting.
- **Monitor for fatigue:** do not allow your dog to become too tired during any physical therapy exercises as the risk of injury increases dramatically due to reduced control. This is especially important at the early phases of treatment when the limb may be weaker from disuse.

## Postoperative Complications

Any surgical procedure may develop complications after surgery. These may include but are not limited to:

- Minor complications:
  - Postoperative swelling and bruising above that normally anticipated. With TTA it is common to have moderate swelling of the ankle (tarsal) joint for 5-7 days after surgery. This may be minimised through appropriate postoperative exercise management.
  - Damage or infection of the skin wound. This risk may be minimised through ensuring your dog does not lick the wound, ensuring a clean soft bed is available, and managing the dressing that will be over the wound when you collect your dog.
- Ongoing progression of OA in the joint. Generally all of the bone cutting (osteotomy) surgeries will have less progression of OA than other currently available techniques. Weight control, exercise management / physiotherapy, use of nutritional supplements (fish oils, chondroitin sulphate / glycosamine etc) and drugs (NSAIDs, Pentosan etc) may all help to manage or minimise progression of OA. Please discuss the relative benefits of these with your surgeon.
- Major complications:
  - Bone infection. Careful management of the overlying skin wound will help to lower the risk. If at any point your dog seems significantly more off colour than previous days, or the limb appears to develop more redness, swelling or a discharge then you should immediately return to have your dog reassessed.
  - Breakage of the implants or bone. Provision of an appropriate environment after surgery is critical to protect the surgical site while the bones heal. This includes provision of a small controlled area with good nonslip flooring, and ensuring strict leash control when out walking.
  - Damage to the cartilage pad (meniscus): Up to 10% of cases may develop a further injury to their meniscus despite surgery having been performed. They may develop a sudden lameness and a distinct clicking can often be heard during motion of the knee joint. A small number of these cases can be managed conservatively, however the majority will need follow up surgery to manage the damaged cartilage.

### Normal Stifle (Knee) Joint

